


PRESENTING CLINICAL SIGNS

DATE History: Grade III/VI sternal murmur. Arrhythmia noted after induction for a dental. Radiographs showed cardiomegaly and a soft tissue opacity seen over the caudal aspect of the heart – report suggested possible mass or PPDH. BNP abnormal.

3/21/23

ECHOCARDIOGRAPHIC FINDINGS

PERFORMED BY: 2D, M-mode, and Doppler study.

Dr. Meredith Swart Left atrial size is normal. The mitral valve is normal. There is mild hypertrophy of the interventricular septum. Left ventricular posterior wall thickness is normal. Left ventricular internal dimensions are normal. Left ventricular systolic function is normal. The aorta and aortic valve appear normal, though there is increased flow velocity in the ascending aorta. Right atrial and right ventricular dimensions are normal. The tricuspid valve is normal. The pulmonary artery and pulmonic valve are normal. No shunting lesions are visualized. No heartworms are visualized. No pericardial effusion or cardiac masses are seen. The liver is adjacent to the heart, suggestive of the presence of a peritoneo-pericardial diaphragmatic hernia (PPDH).

INTERPRETED BY

Keith Blass, DVM,
MS, DACVIM
(Cardiology)

PATIENT LA/Ao – 1.41
IVSd – 6.1 mm
LVPWd – 4.4 mm
LVIDd – 15.2 mm
LVIDs – 7.3 mm
FS – 52%

Barney Horton

SPECIES LVOT – 3.06 m/s
RVOT – 1.27 m/s

Feline

ASSESSMENT/RECOMMENDATIONS

BREED Hypertrophic cardiomyopathy (HCM)
Likely peritoneo-pericardial diaphragmatic hernia (PPDH)

DLH

SEX This examination demonstrates mild hypertrophy of Barney’s interventricular septum, which is likely consistent with the presence of HCHM, though systemic hypertension and hyperthyroidism should be ruled out as possible contributing factors. The hemodynamic effects of the hypertrophy appear to be mild, as Barney does not have secondary dilation of his left atrium. As such, Barney’s current risk for the development of congestive heart failure and/or thromboembolic disease appears to be fairly low.

MN

AGE Also seen in this exam is Barney’s liver, which is adjacent to his heart. This is highly suggestive of the presence of a PPDH, though CT can be considered for confirmation. It’s unclear whether the PPDH is an incidental finding, as I can’t rule out its presence as a contributor to the arrhythmia Barney experienced while anesthetized (if it resulted in decreased perfusion).

13 y

WEIGHT An ECG is recommended to further evaluate Barney’s arrhythmia.

14 lb No therapy is recommended at this stage of Barney’s HCM. If a PPDH is confirmed, surgical correction is likely indicated even though it may be an incidental finding at this time.

HOSPITAL NAME Given that an arrhythmia developed during anesthesia and cardiac disease is present, I recommend avoiding the use of alpha-2 agonists, ketamine, telazol, and, if possible, anticholinergics in the anesthetic protocol, as well as reducing the IV fluid rate by 25%. If possible, monitoring of heart rhythm, blood pressure, and pulse oximetry are recommended during the procedure.

Swart Veterinary
Imaging

REFERRING VET

Dr. Swart



A recheck echocardiogram is recommended in 6 months.

DATE

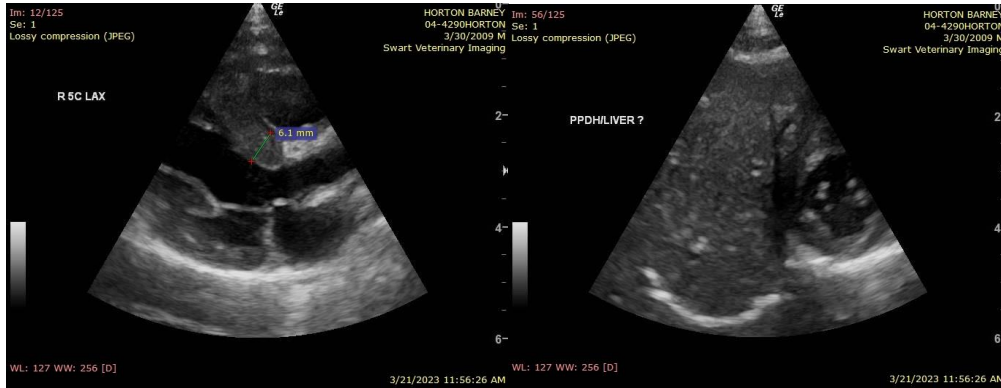
3/21/23

PERFORMED BY:

Dr. Meredith Swart

INTERPRETED BY

Keith Blass, DVM,
MS, DACVIM
(Cardiology)



The information and recommendations provided are based on the images presented by the referring veterinarian. No evaluation can be communicated regarding pathology that was not visible in the image/video clips provided.

PATIENT

Barney Horton

Thank you for this referral. If the clinical or image interpretation does not parallel your findings or if I can be of any further assistance please contact me.

SPECIES

Feline

Keith Blass, DVM, MS, DACVIM (Cardiology)
KeithBlass@gmail.com
631-804-5754

BREED

DLH

SEX

MN

AGE

13 y

WEIGHT

14 lb

HOSPITAL NAME

Swart Veterinary
Imaging

REFERRING VET

Dr. Swart